

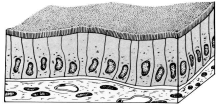
4.

Lecture # 4.

Nerve tissue and nervous system. Prof. Wojciech Sawicki

Seminar/Practical class # 4. Epithelial tissue, glands.

slides:



simple columnar
epithelium

- simple squamous epithelium - cornea (slide # 3a),
- simple columnar epithelium - jejunum (slide # 51a),
- simple cuboidal epithelium - thyroid gland (slide # 8),
- stratified squamous epithelium – cornea (slide # 3a),
- pseudostratified columnar epithelium - trachea (slide # 60),
- stratified cuboidal epithelium (transitional) - urinary bladder (slide # 67),