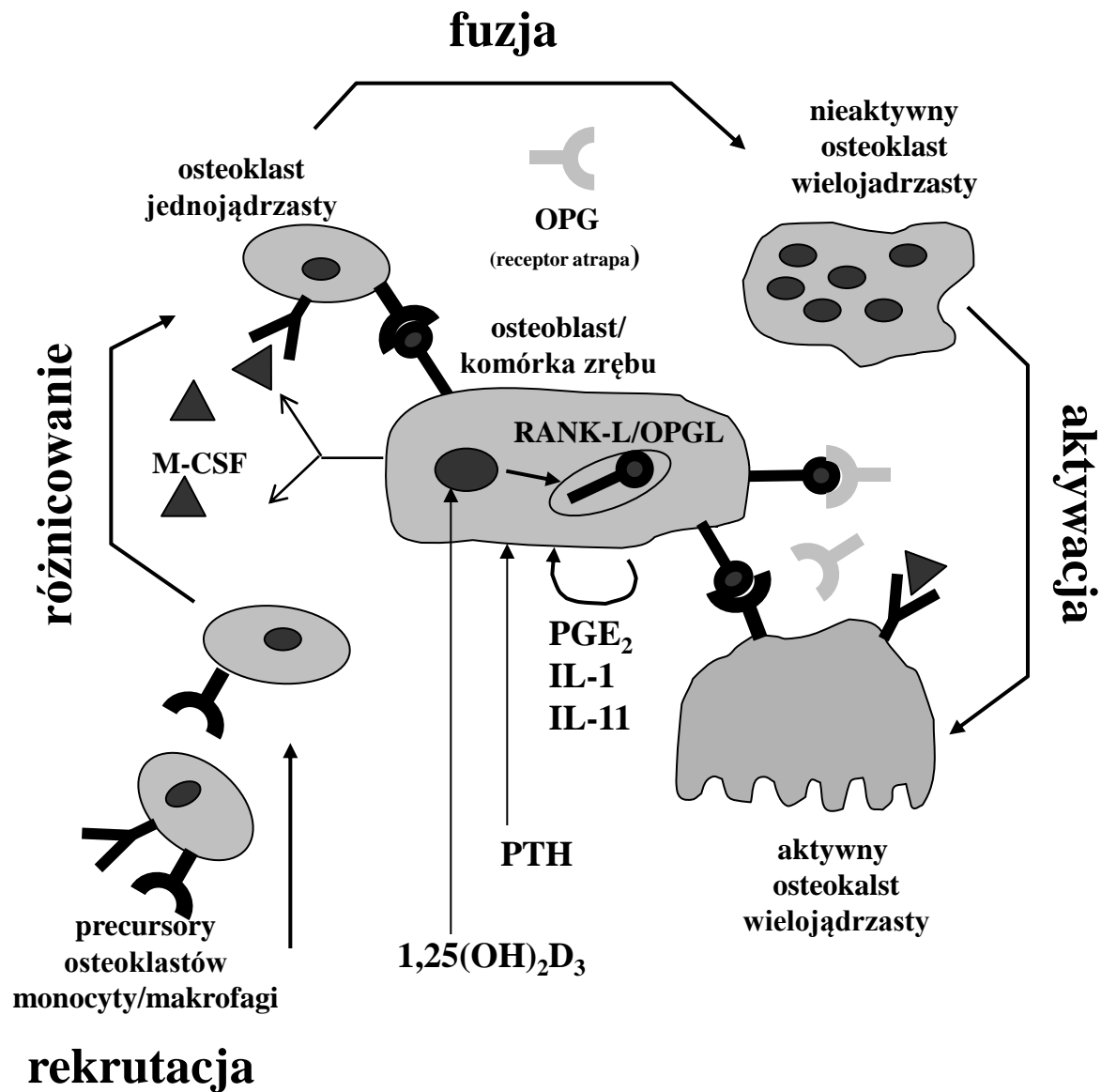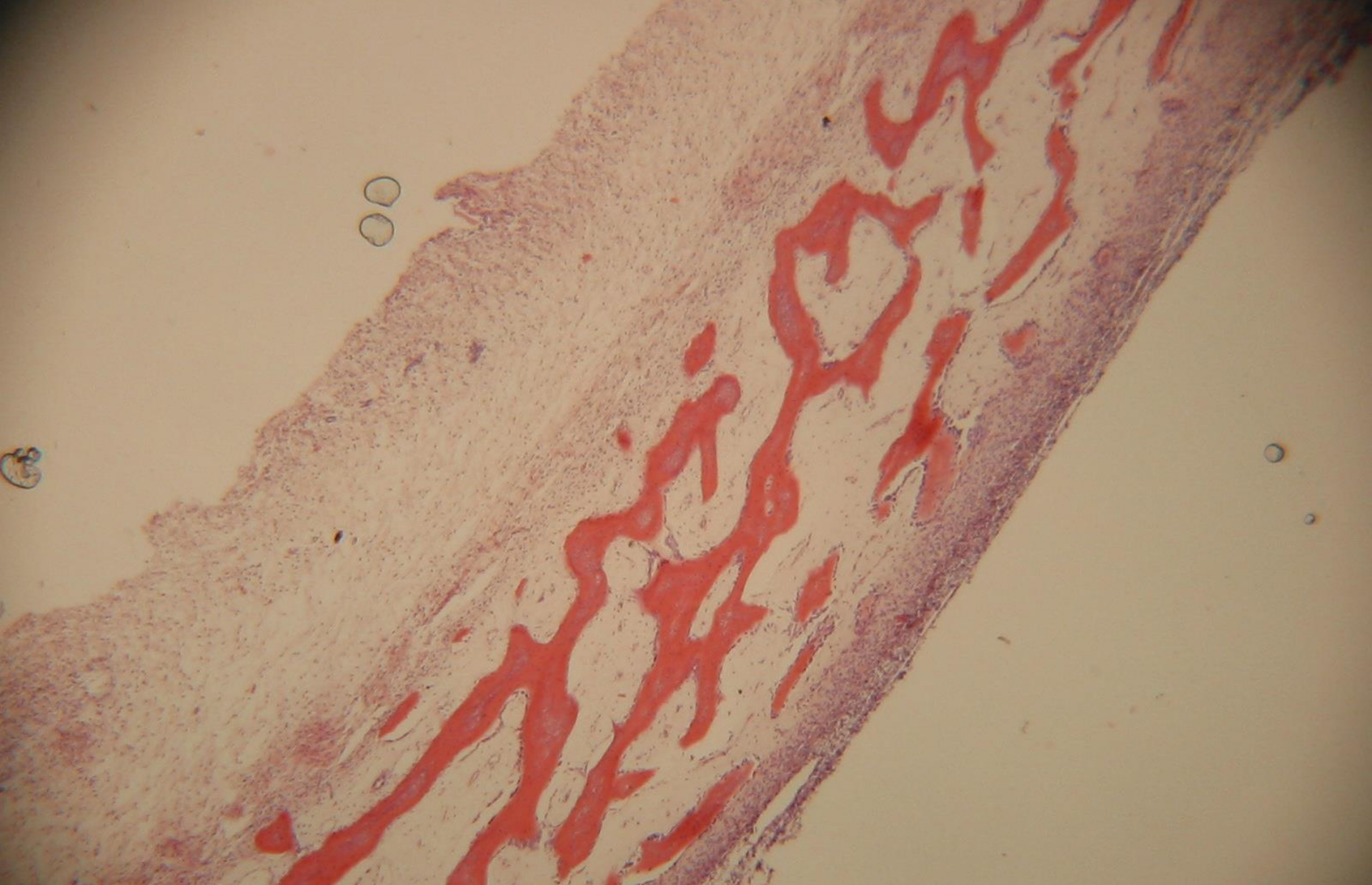
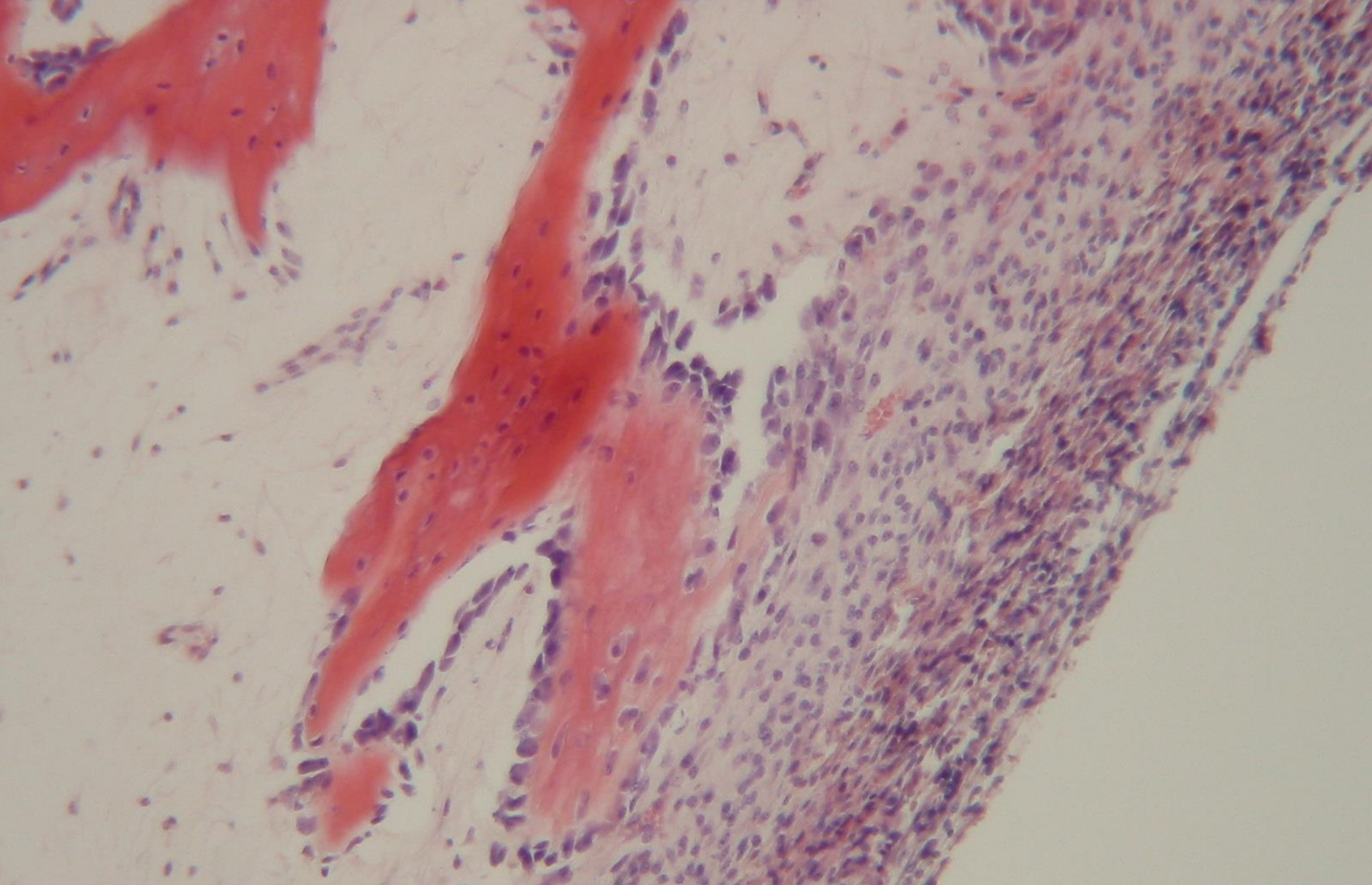


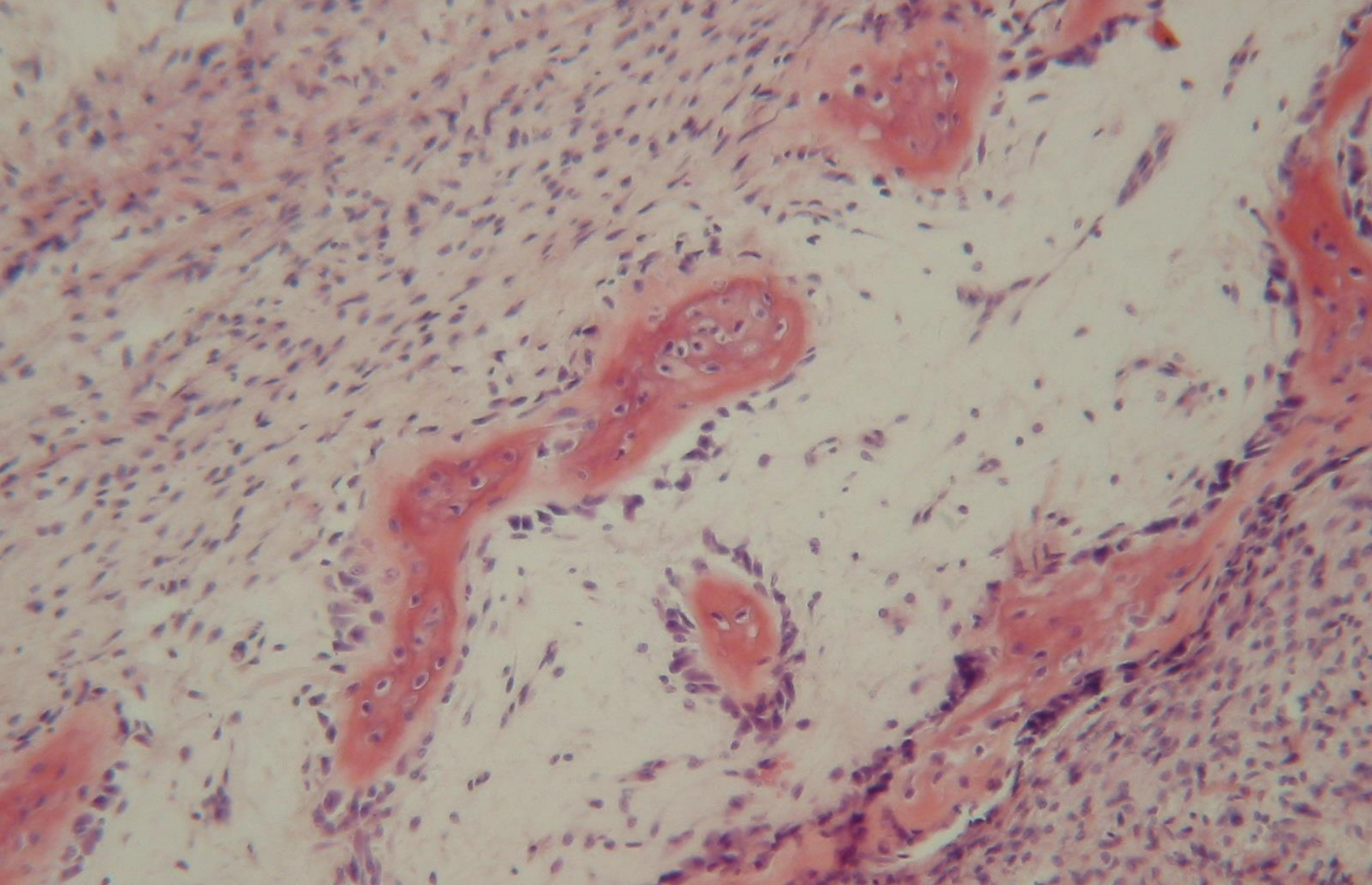
Komórki kości



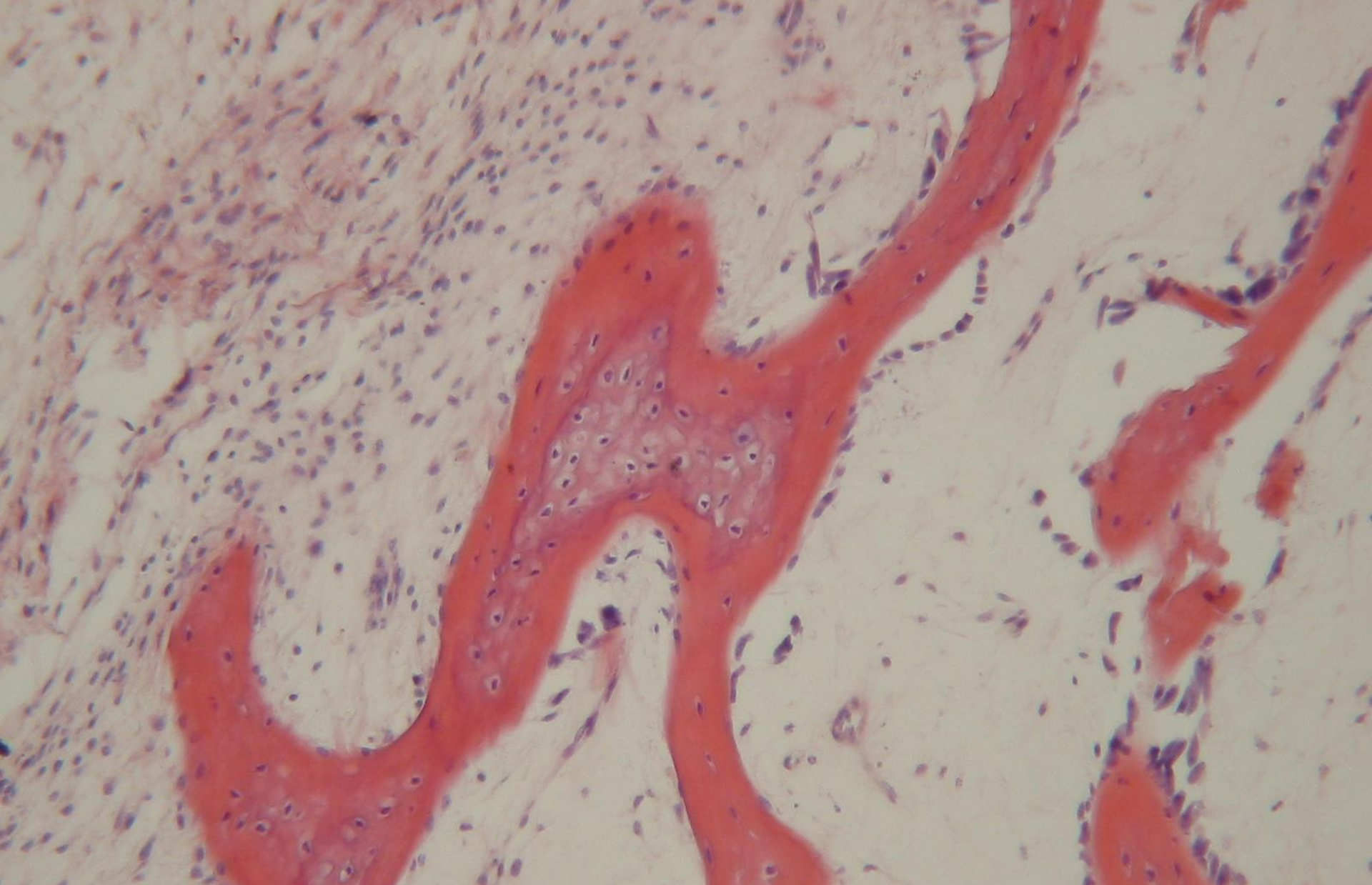
**Powstawanie kości na podłożu błoniastym
Układ beleczek kostnych**



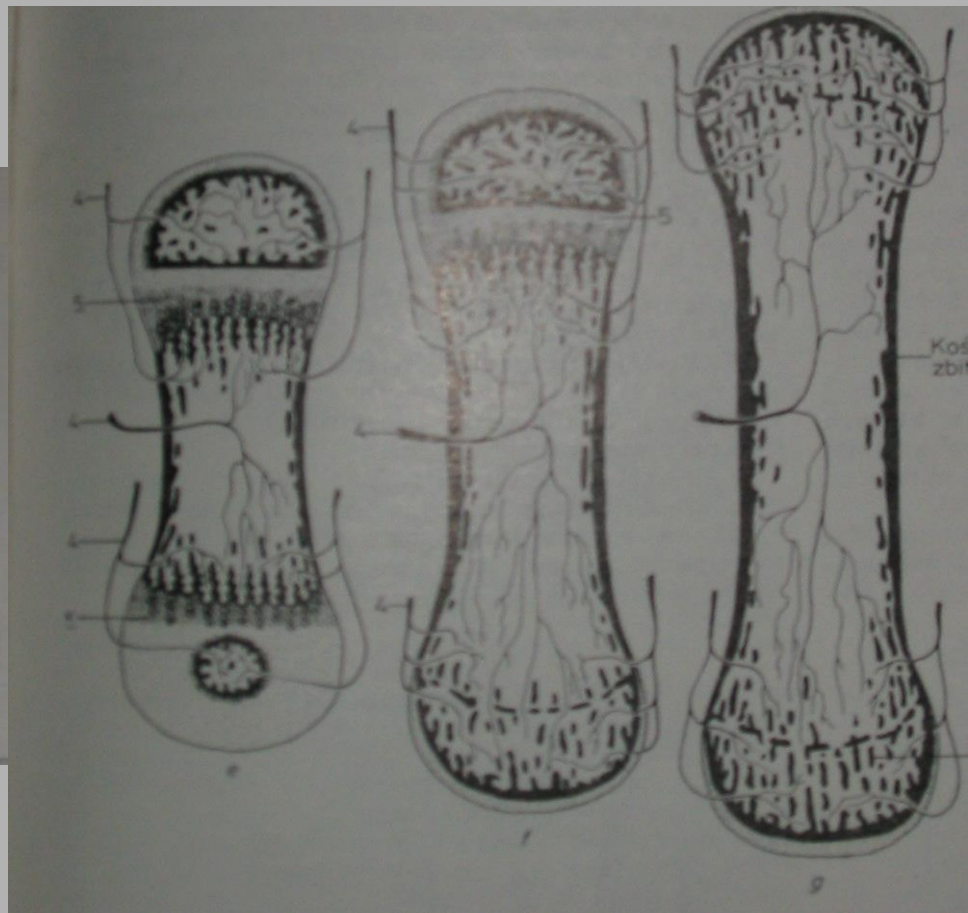
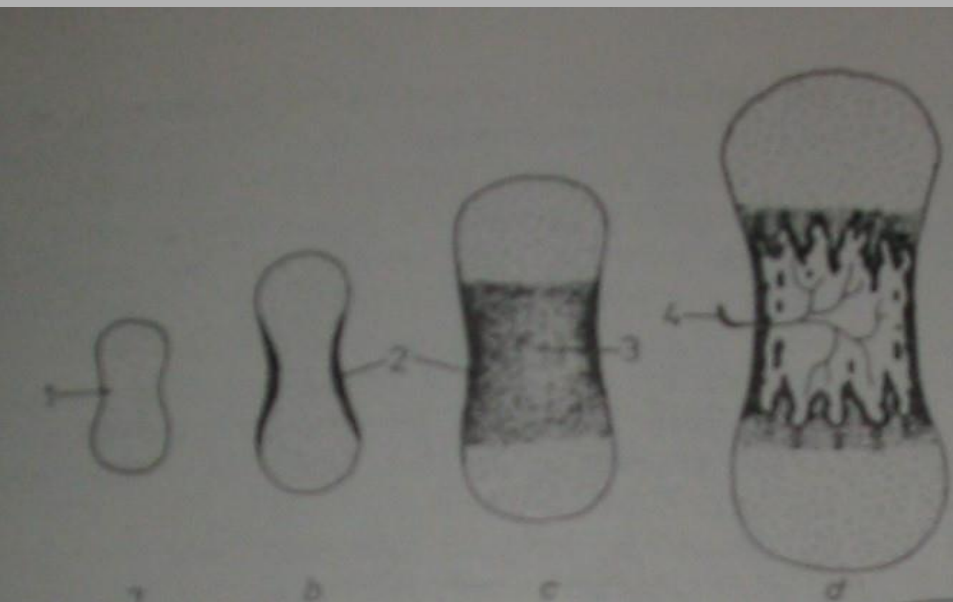
**Powstawanie kości na podłożu błoniastym
Struktura beleczki**



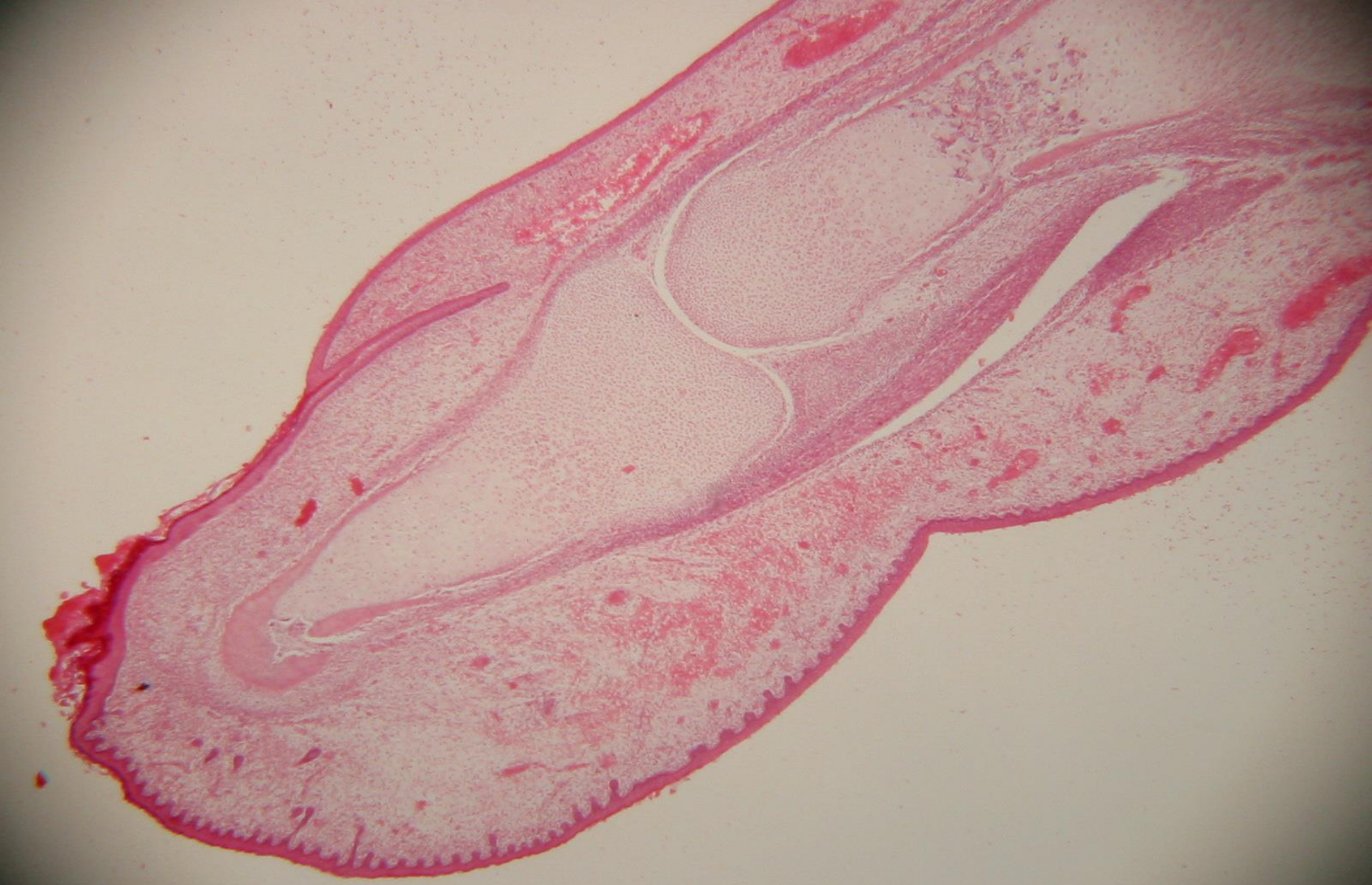
**Powstawanie kości na podłożu błoniastym
Układ beleczek kostnych, kostnienie**



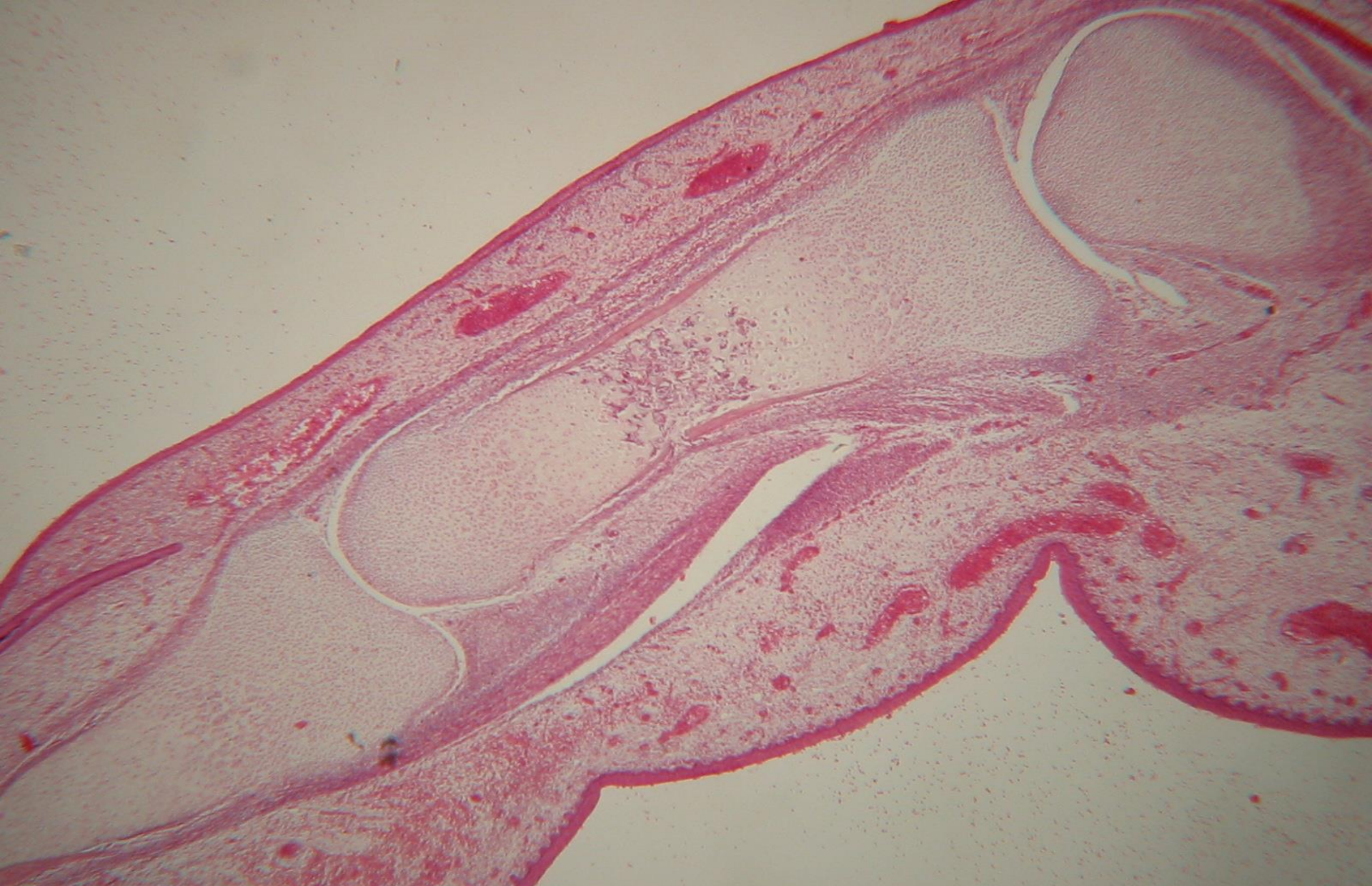
**Powstawanie kości na podłożu błoniastym
Struktura beleczki, kostnienie**



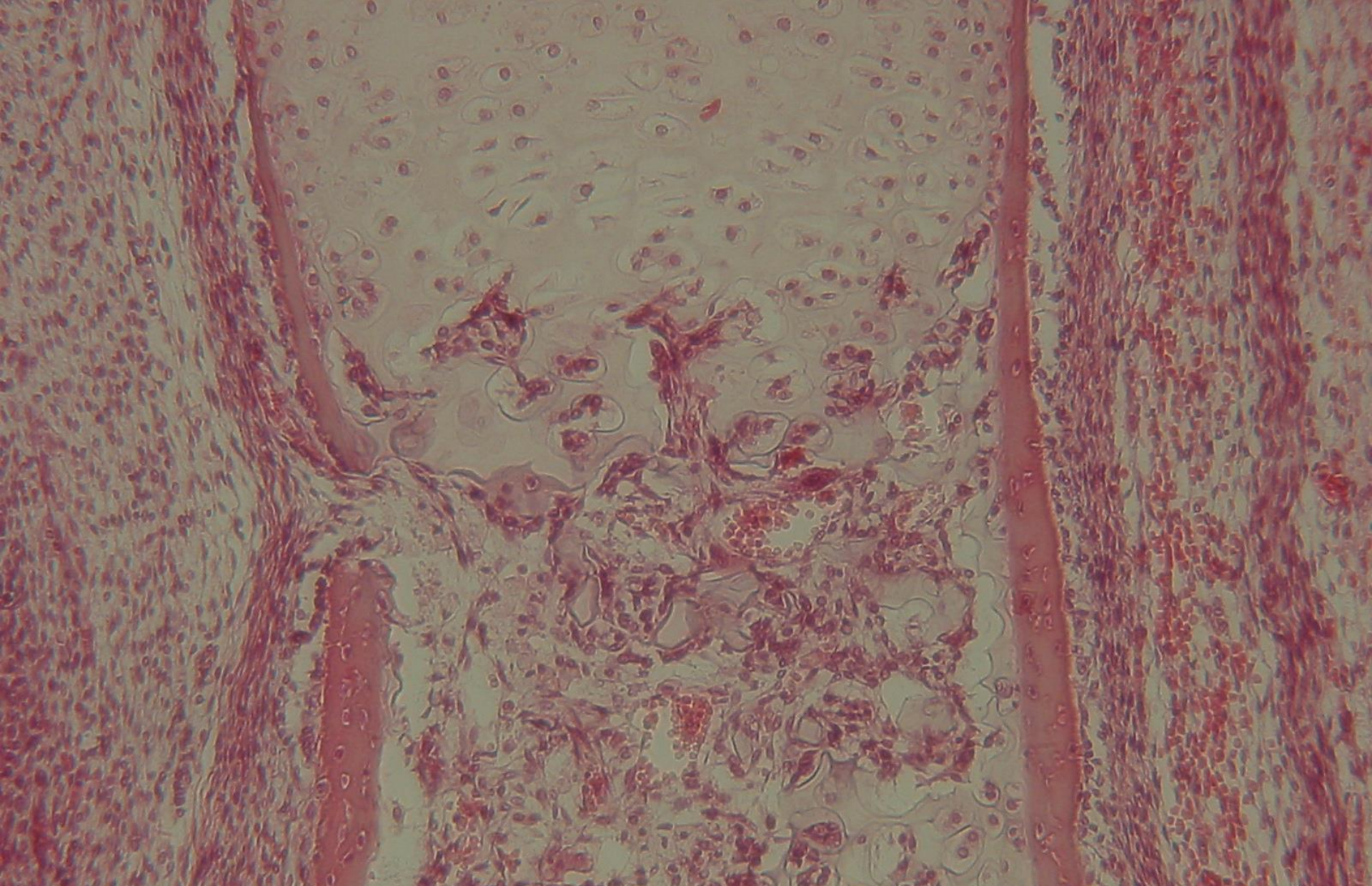
Fazy kostnienia na podłożu chrzęstnym



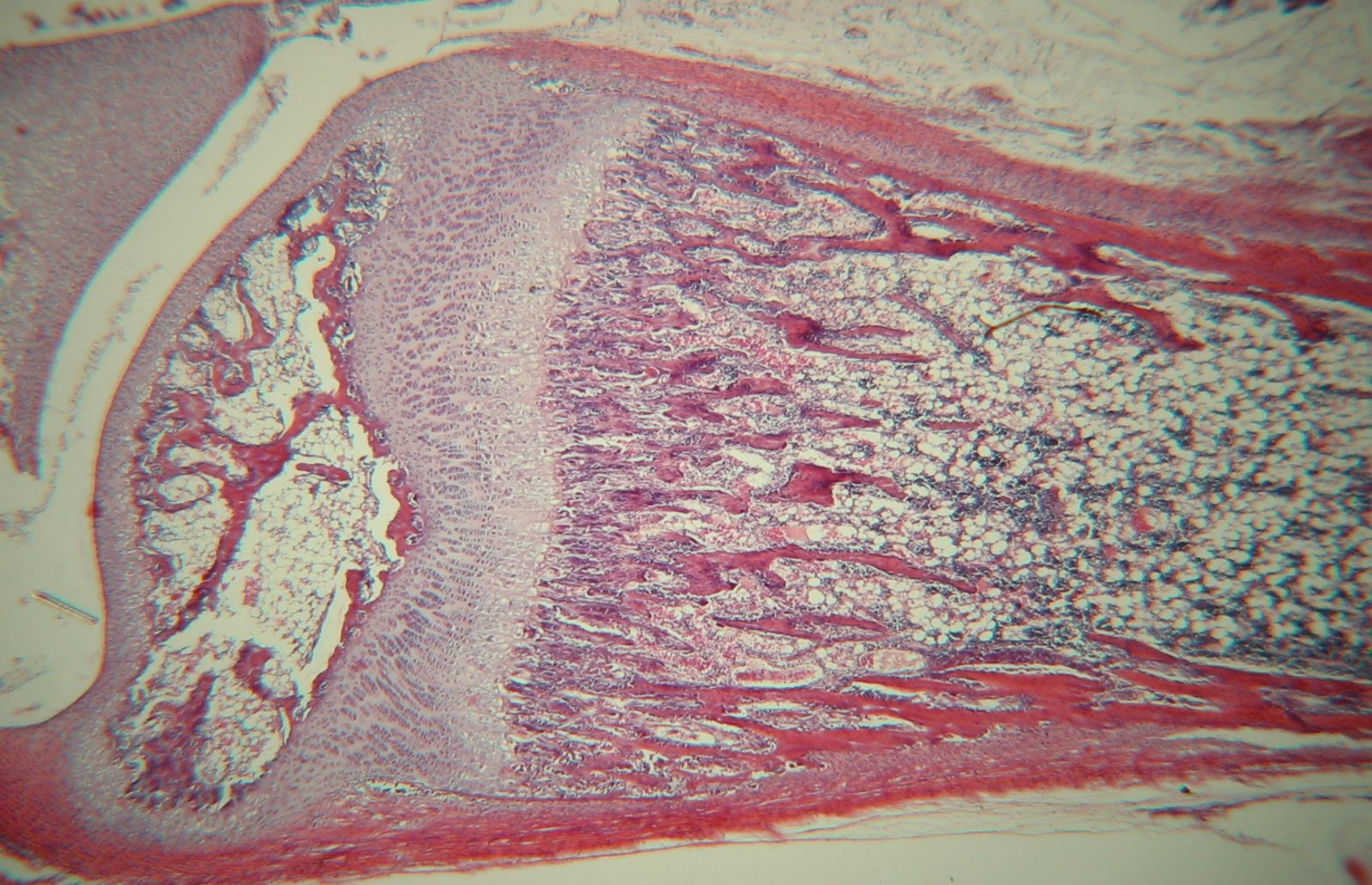
**Wczesne stadium kostnienia na podłożu chrzęstnym
Model chrzęstny**



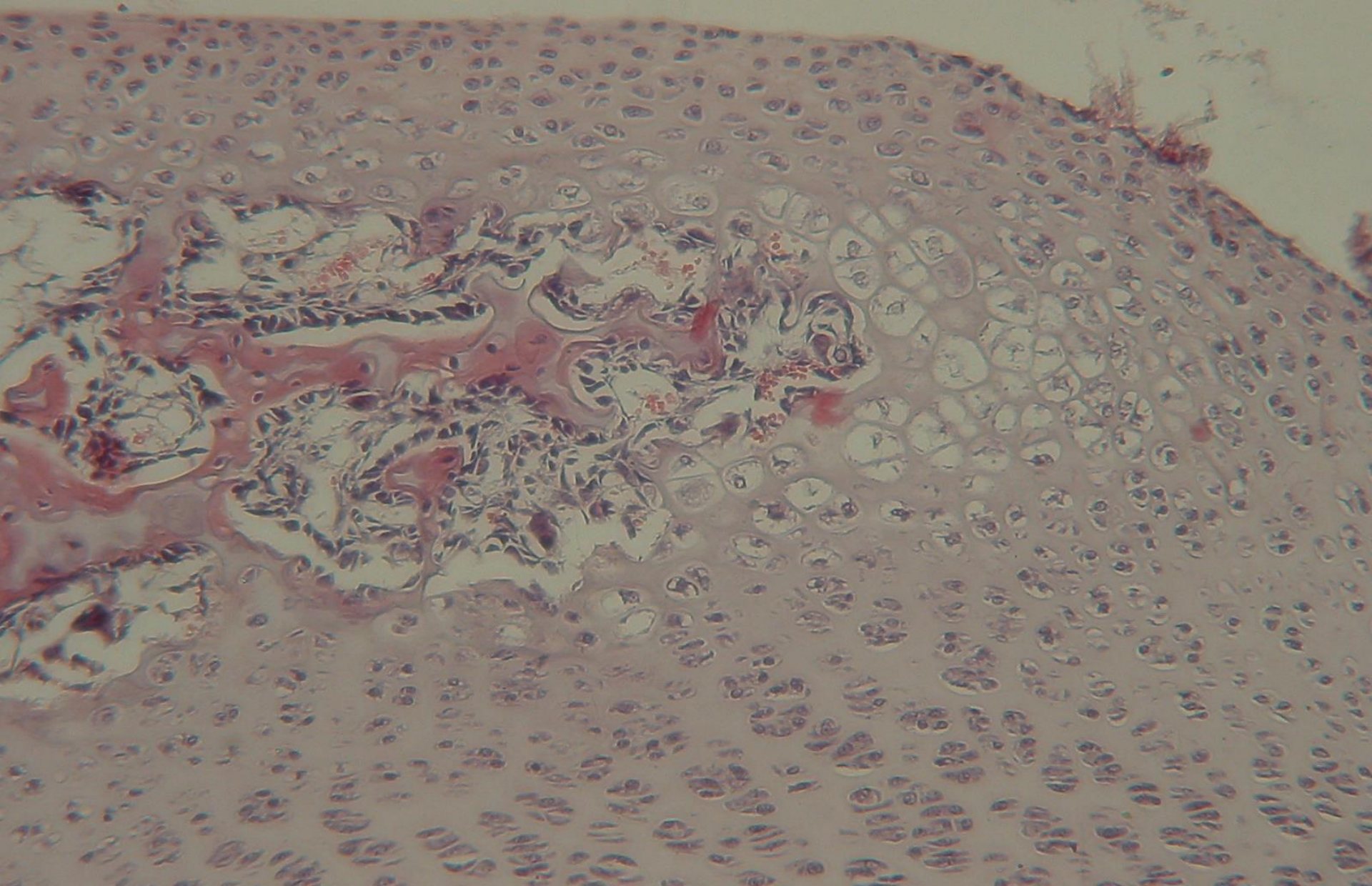
**Wczesne stadium kostnienia na podłożu chrzęstnym
Mankiet kostny, pierwotny punkt kostnienia**



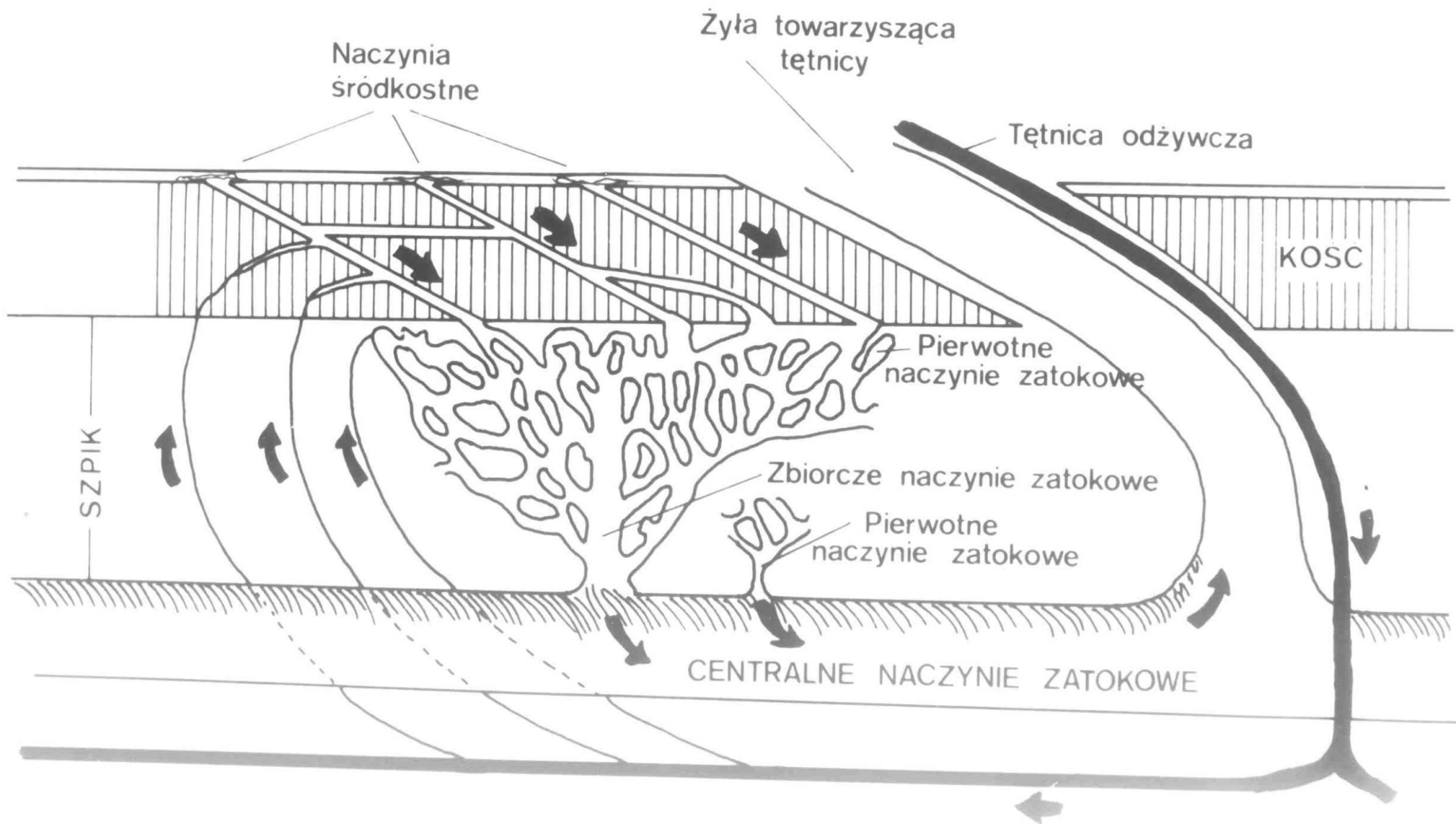
**Wczesne stadium kostnienia na podłożu chrzęstnym
Mankiet kostny, pierwotny punkt kostnienia**



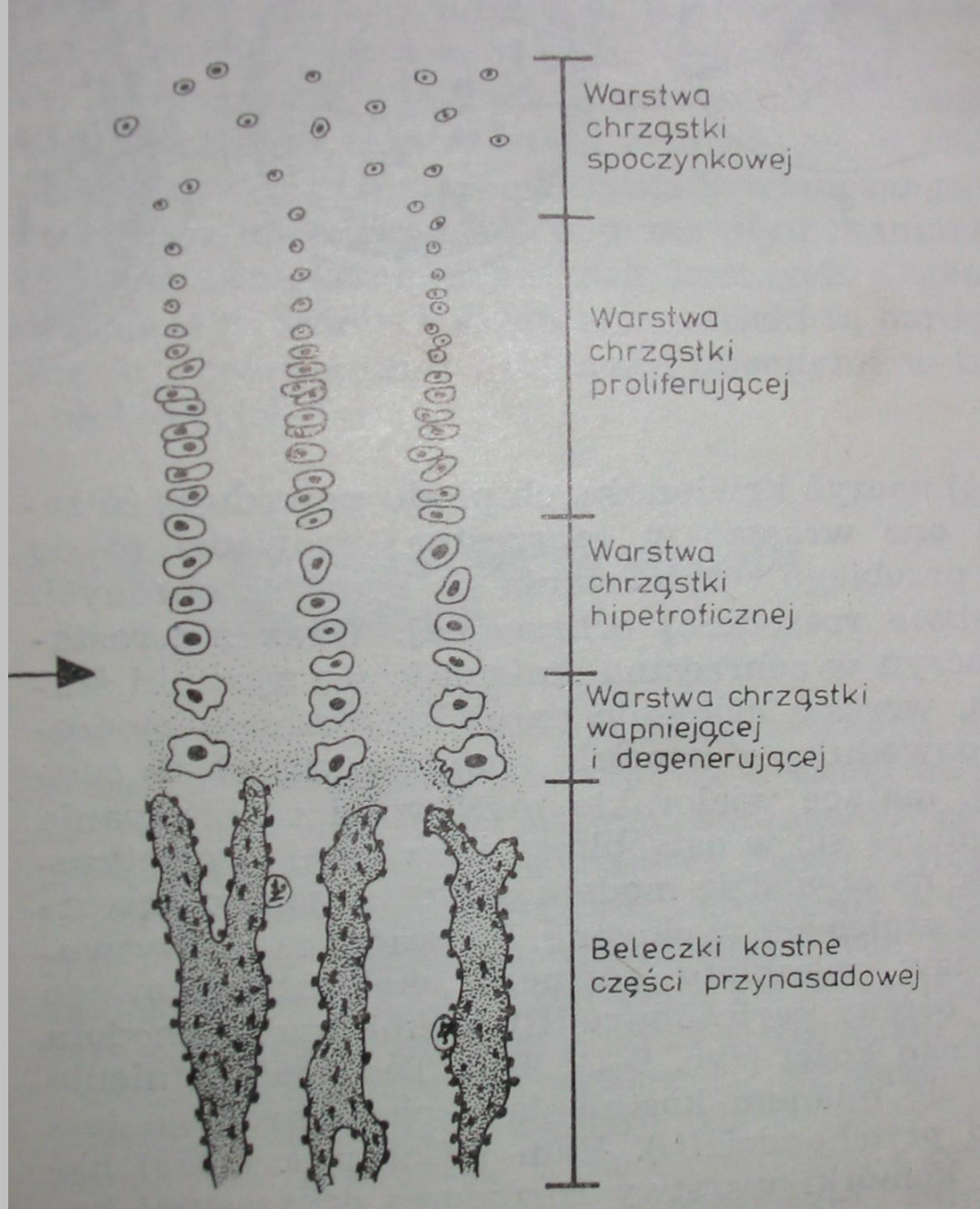
**Późne stadium kostnienia na podłożu chrzęstnym
Wtórny punkt kostnienia, chrząstka wzrostowa**



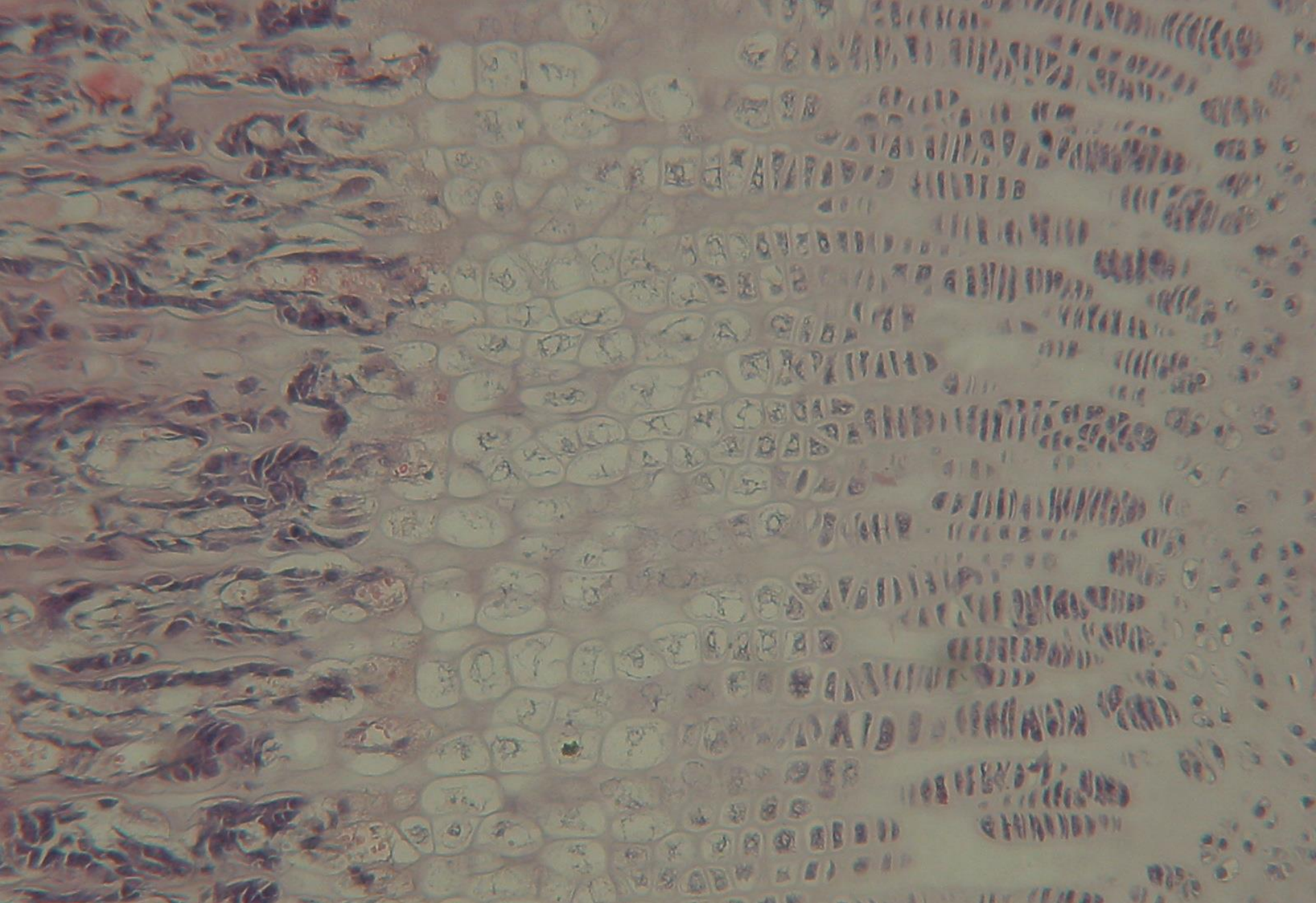
**Późne stadium kostnienia na podłożu chrzęstnym
Wtórny punkt kostnienia**



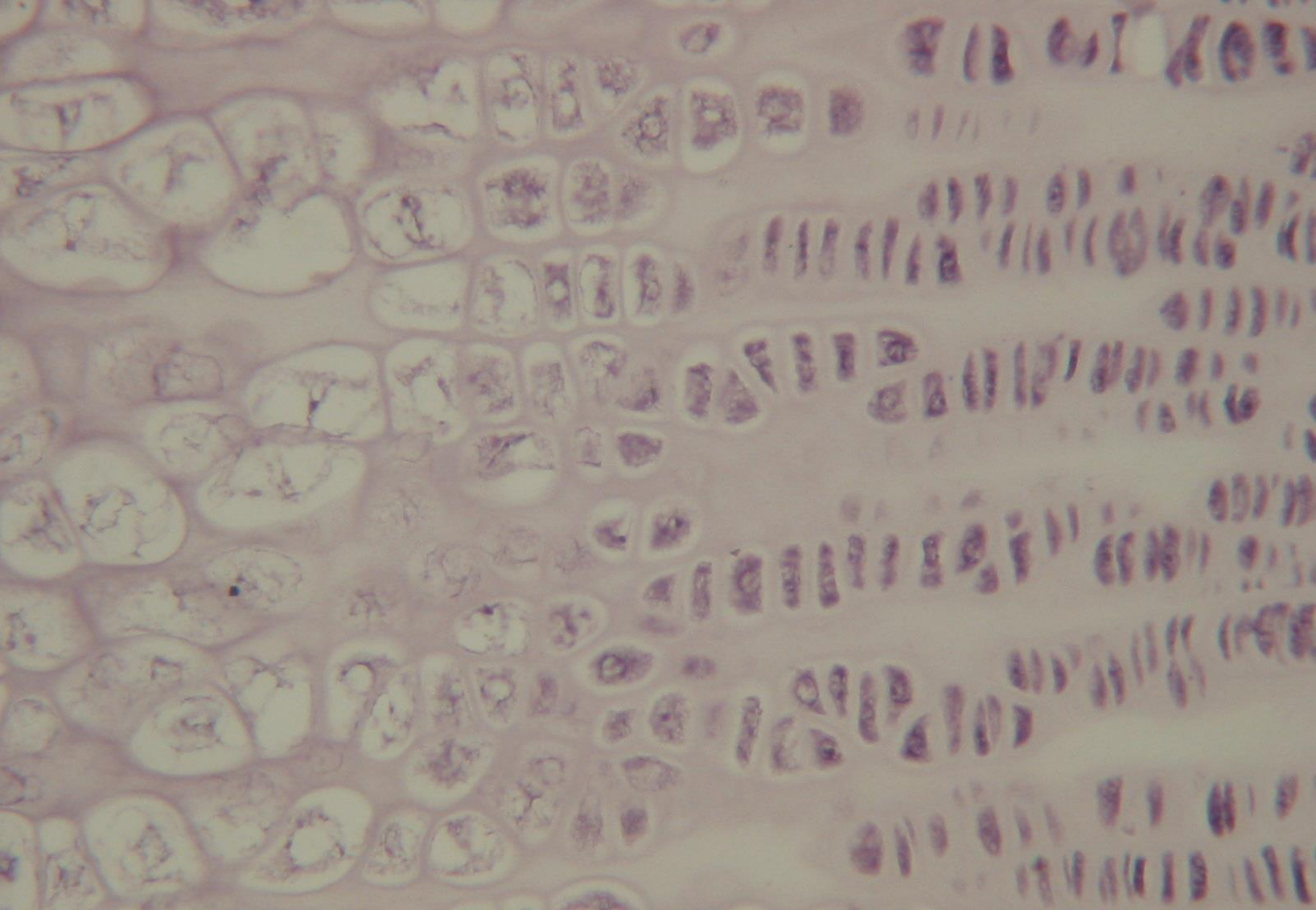
Ukrwienie kości (schemat)



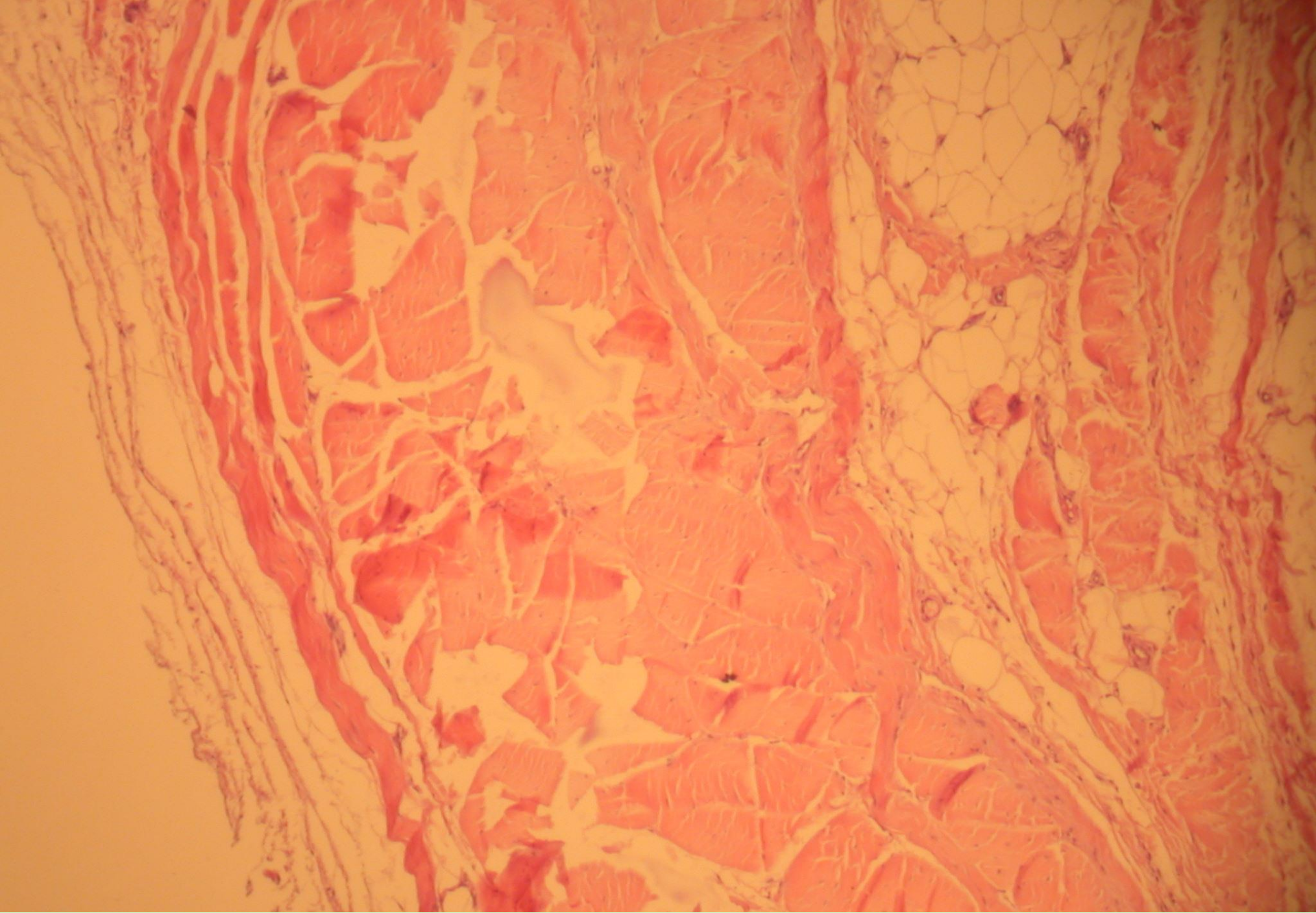
Strefy chrząstki wzrostowej



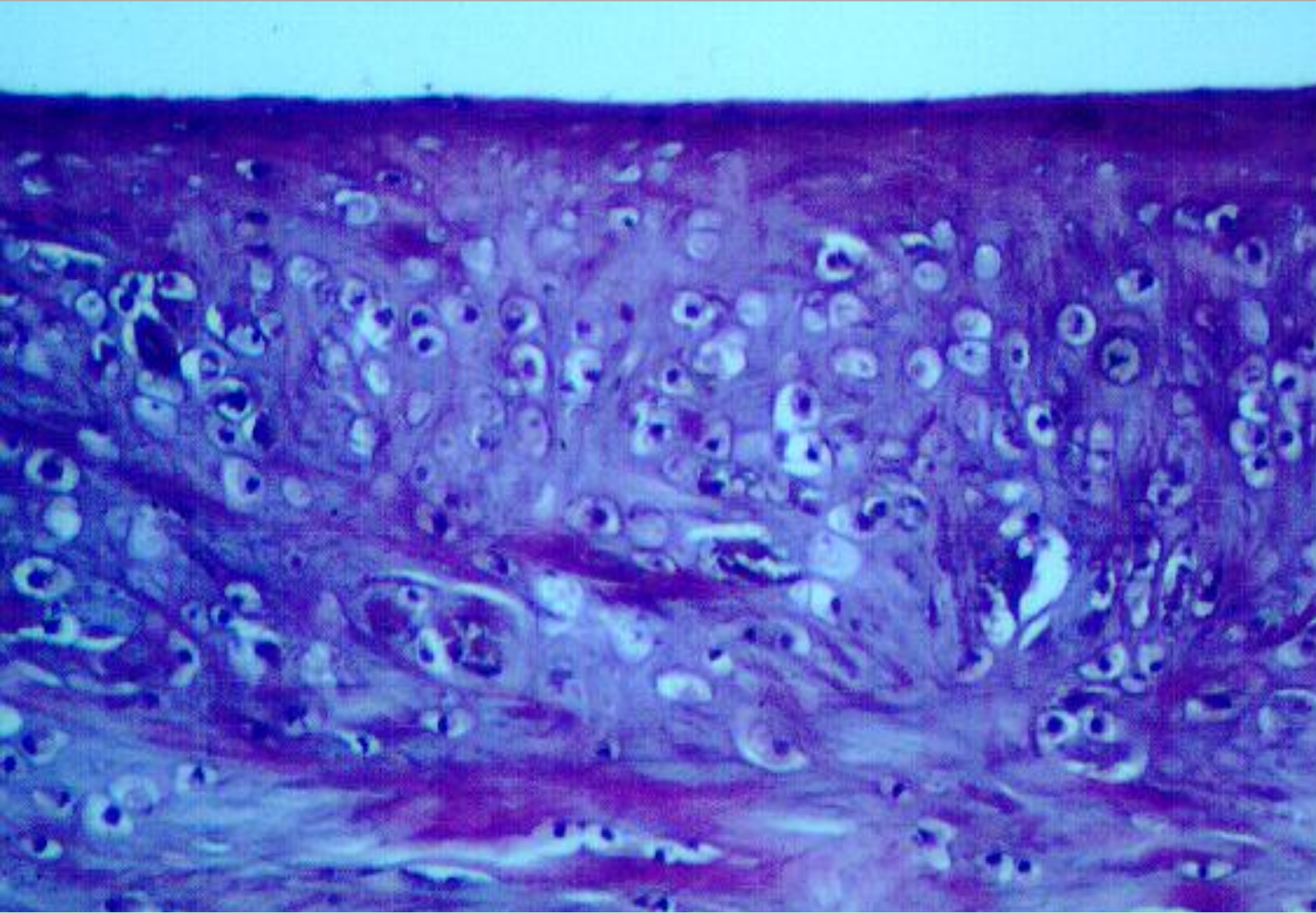
Chrząstka wzrostowa



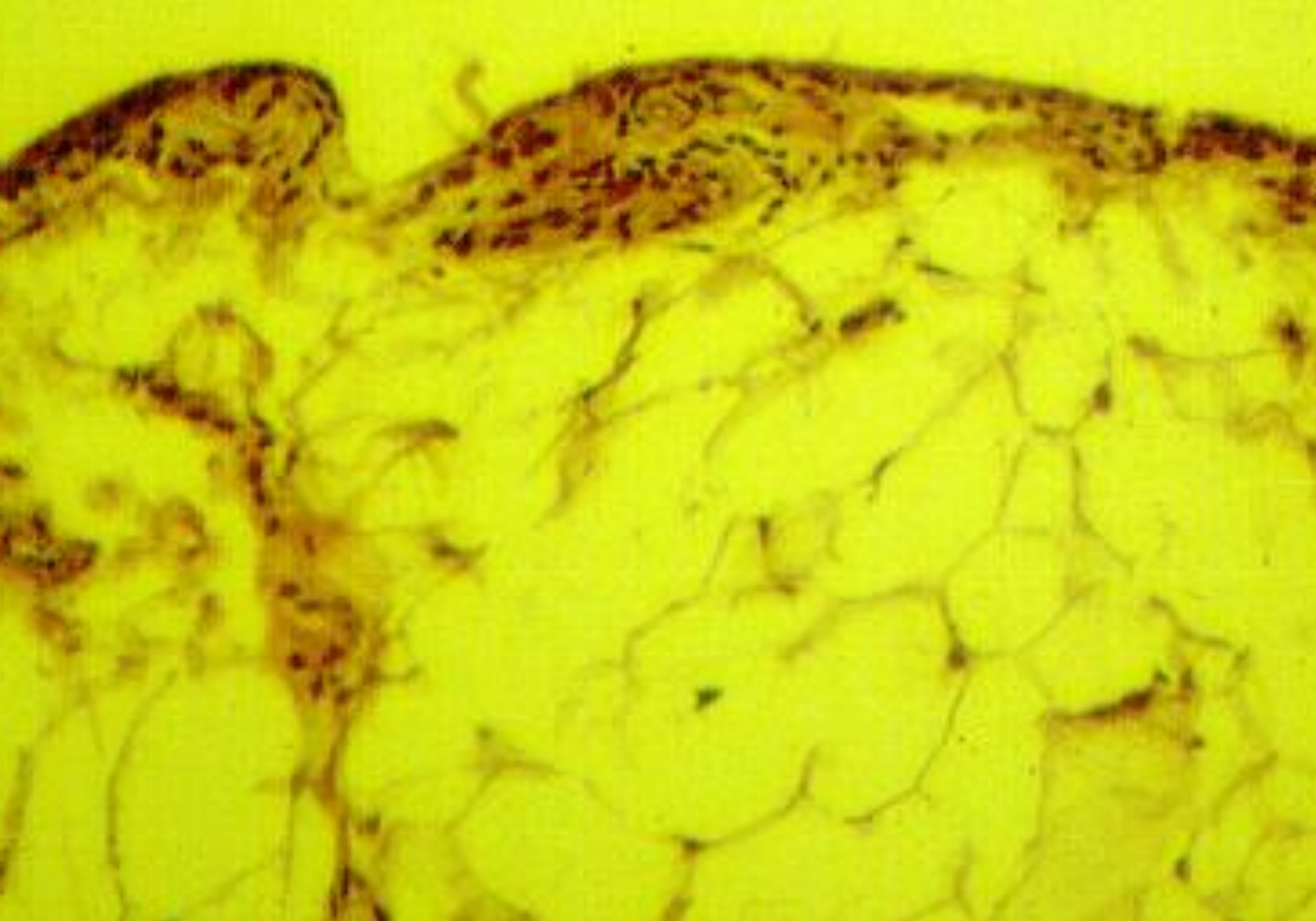
Chrząstka wzrostowa



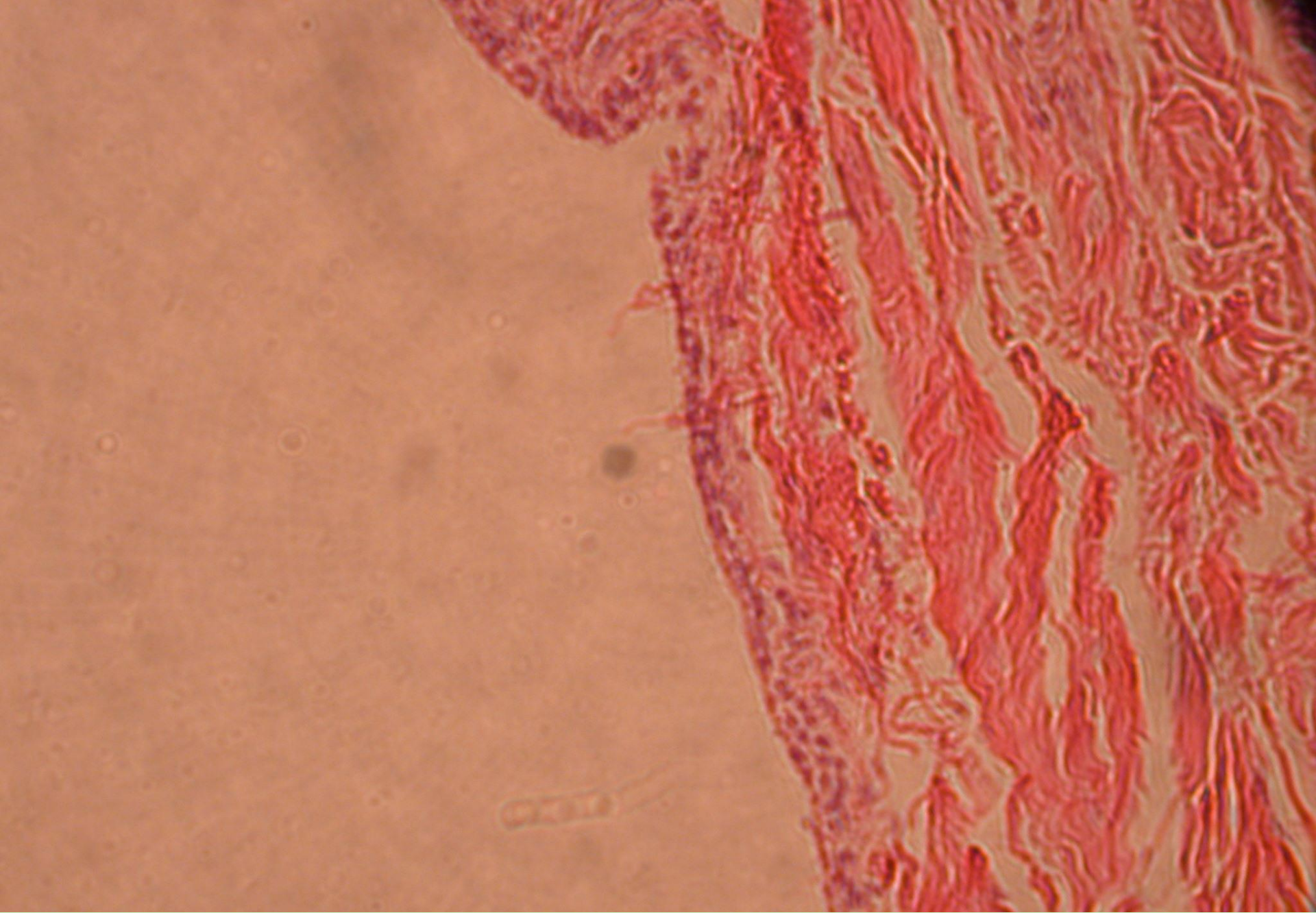
Torebka stawowa



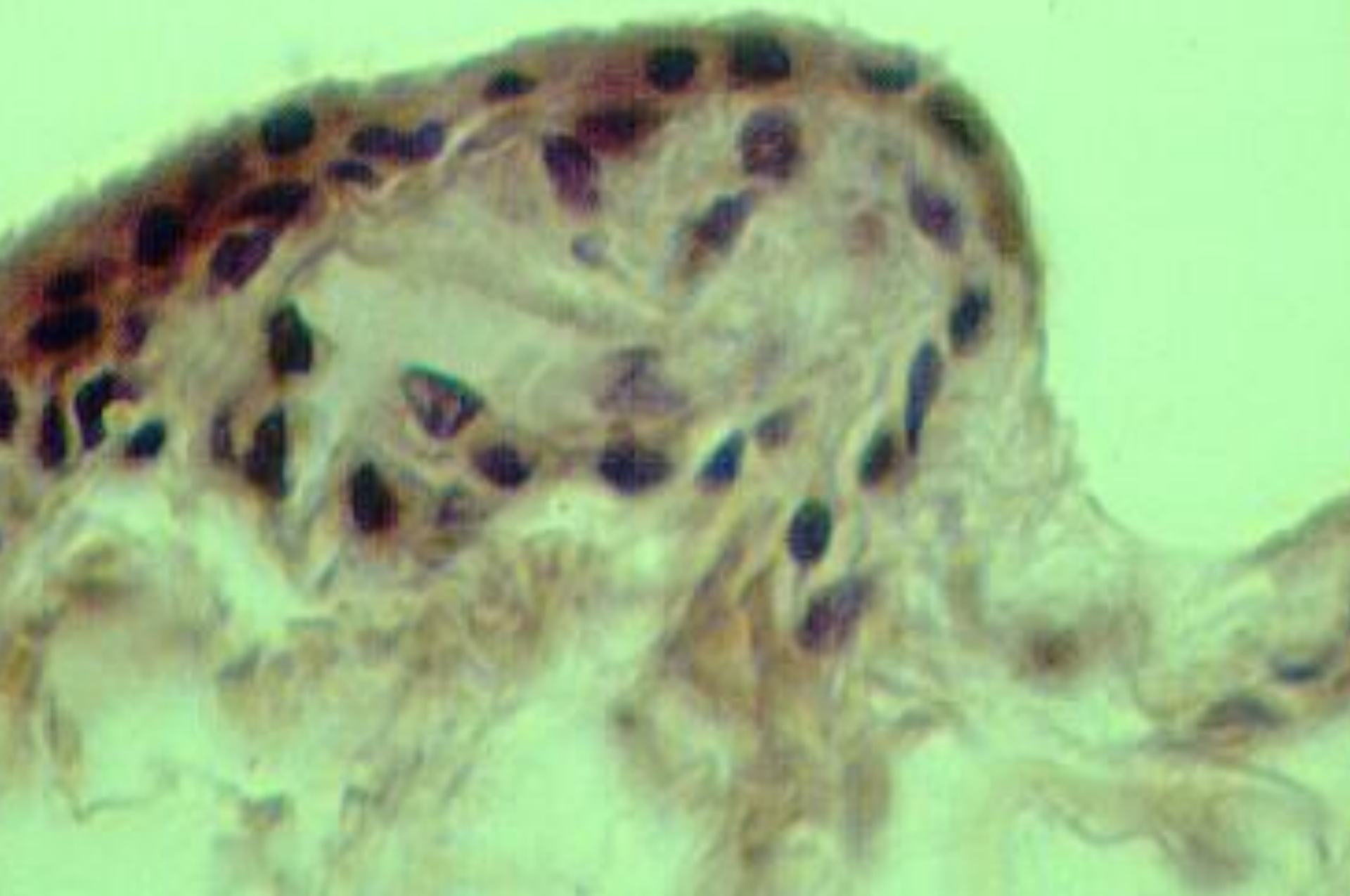Torebka stawowa - królika



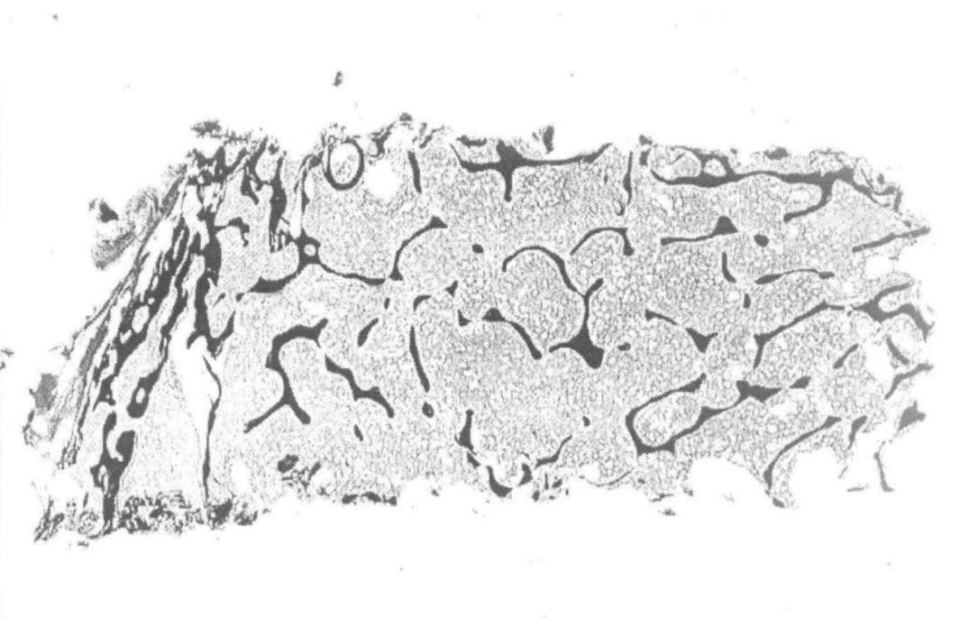
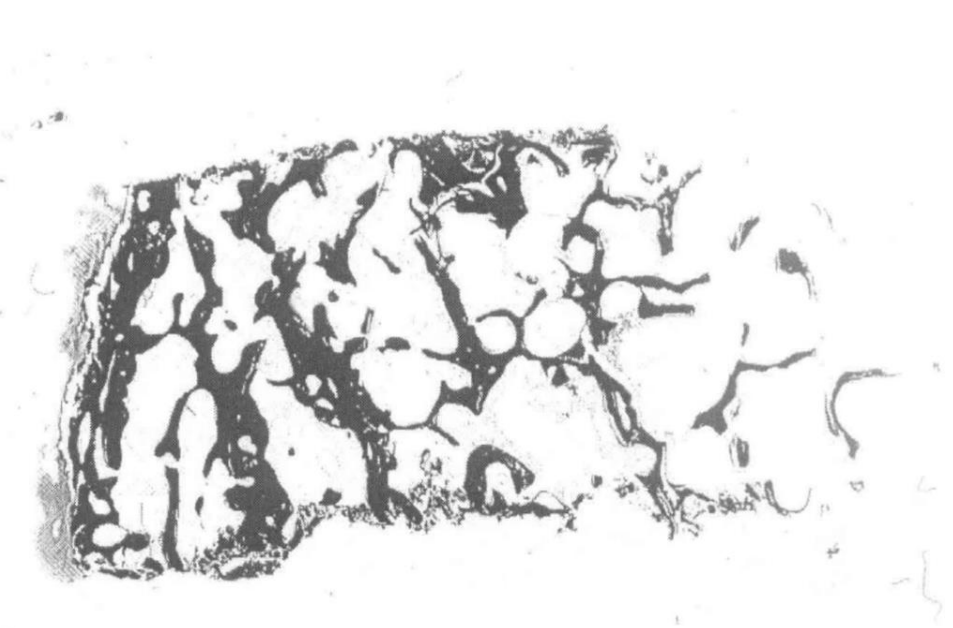
BŁONA MAZIOWA



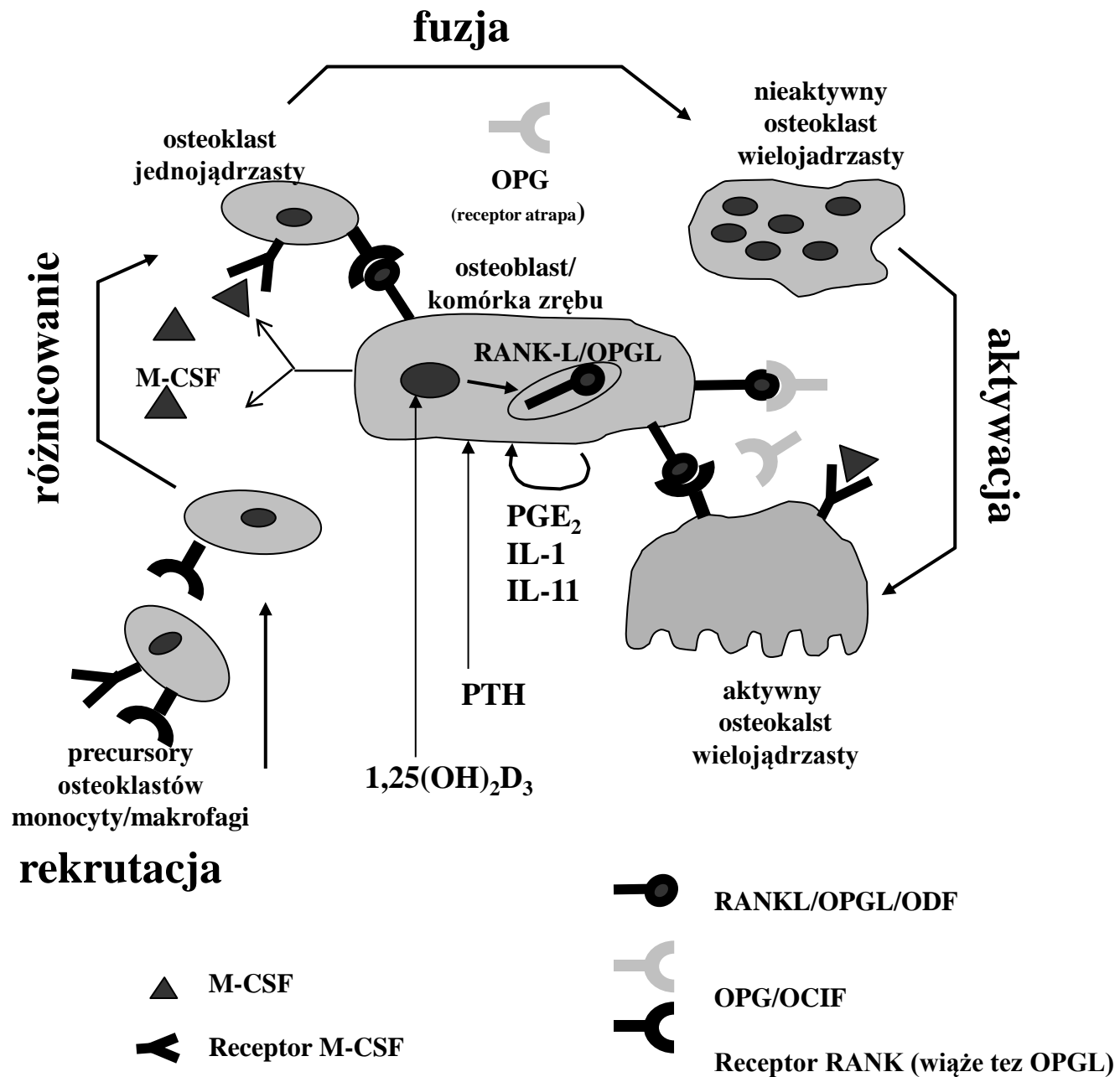
Błona maziowa



BŁONA MAZIOWA



Beleczki kostne
kość prawidłowa, kość osteoporotyczna

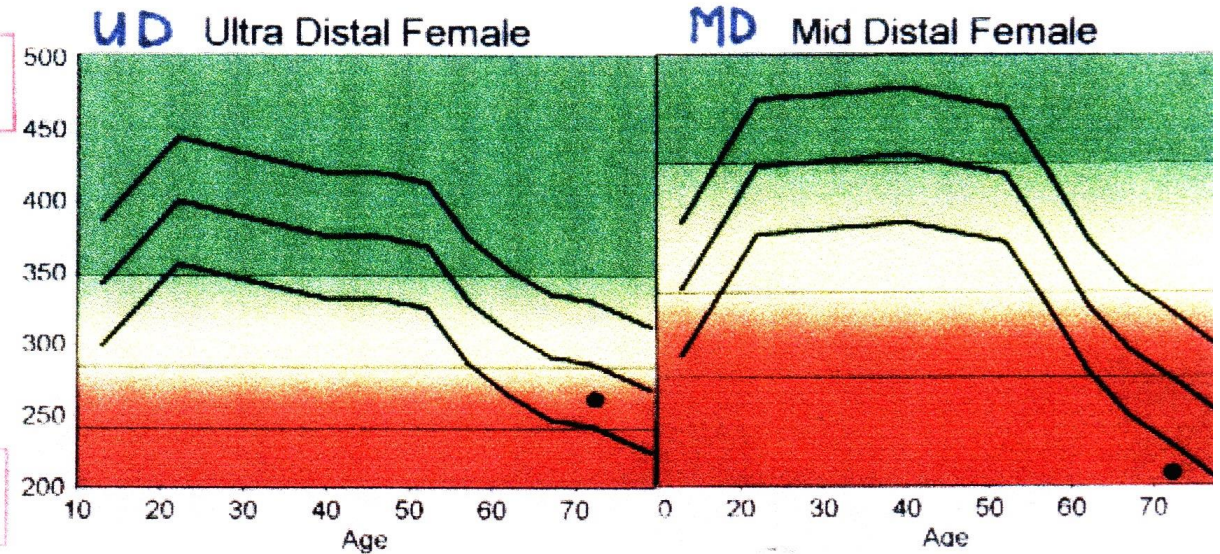

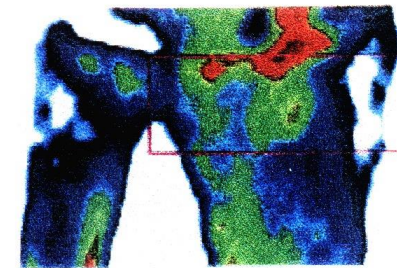
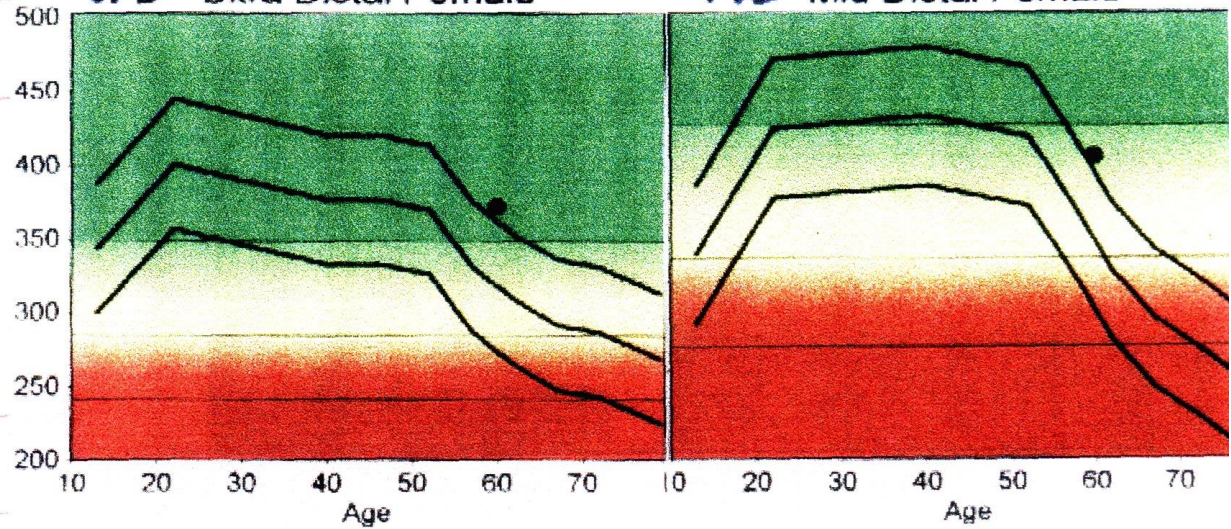

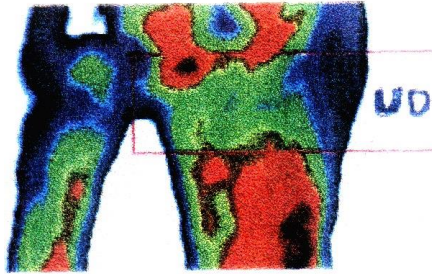


Regulacja metabolizmu kości

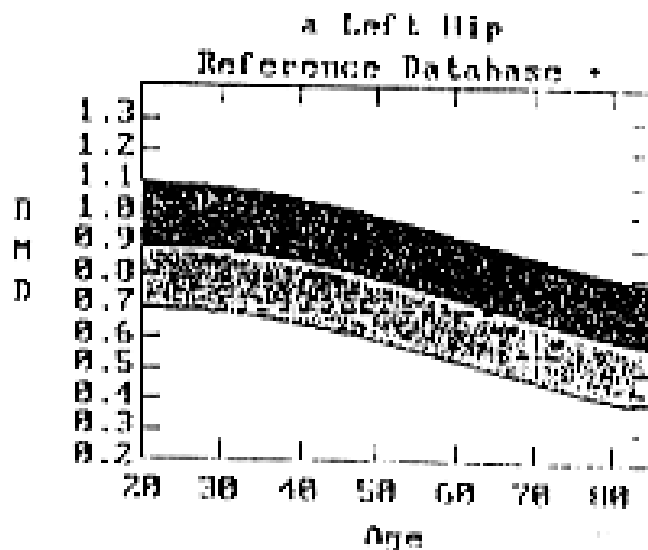
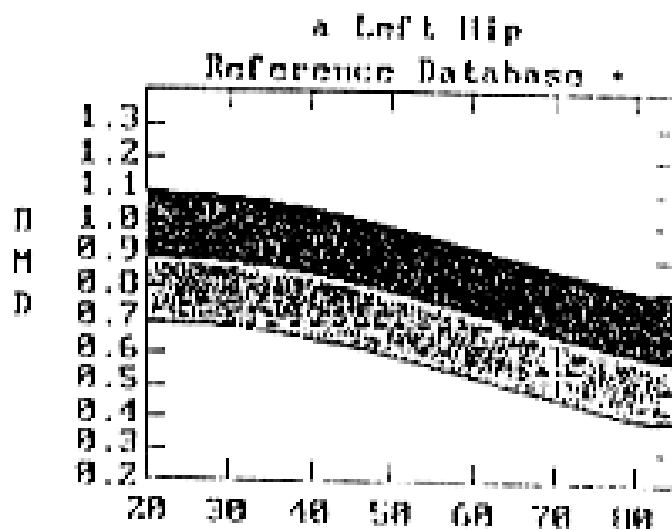
OSTEOPLAN+ p-DXA

UD Ultra Distal Female

MD Mid Distal Female

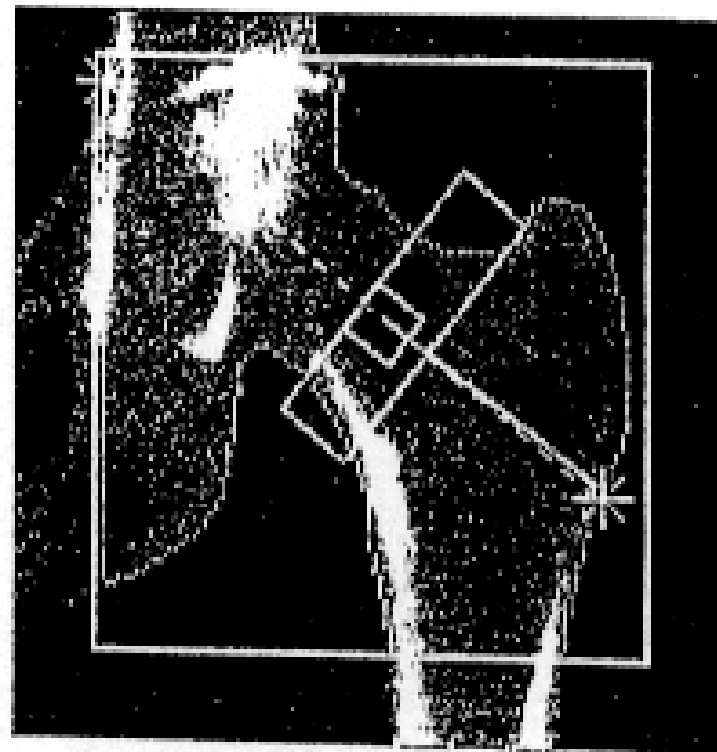


Densytogram kości - przedramię



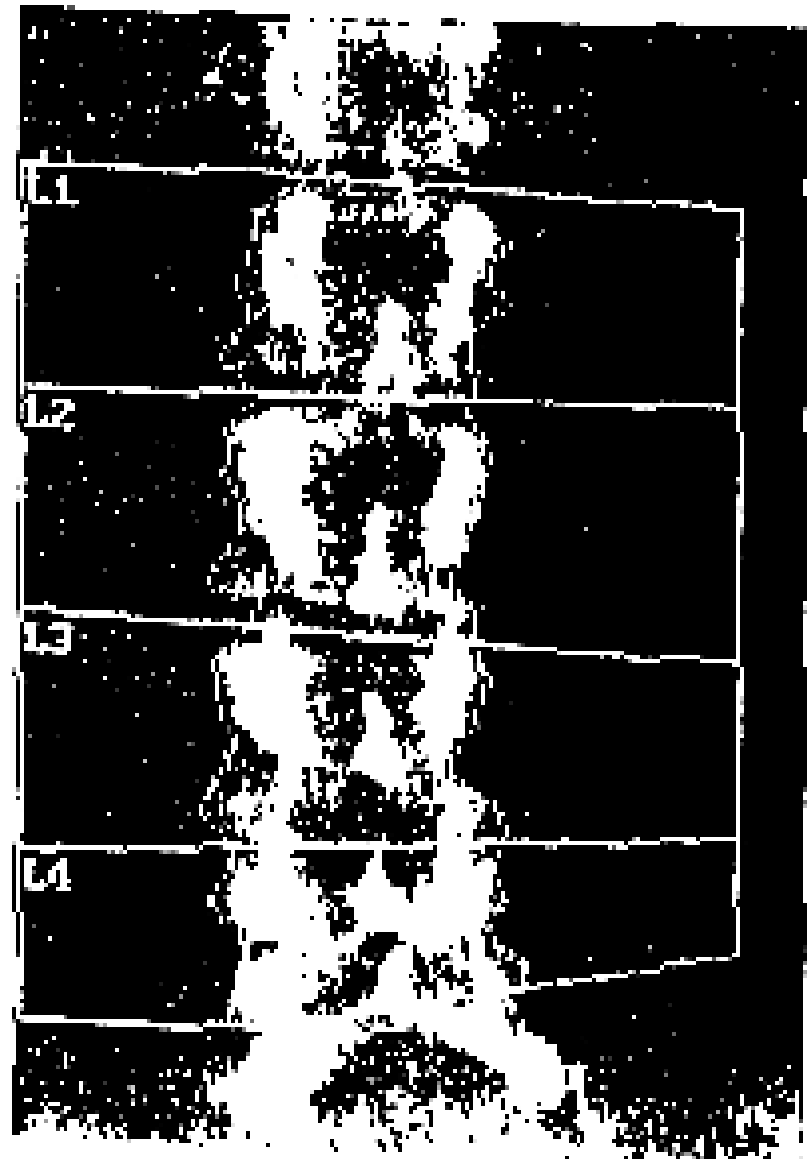
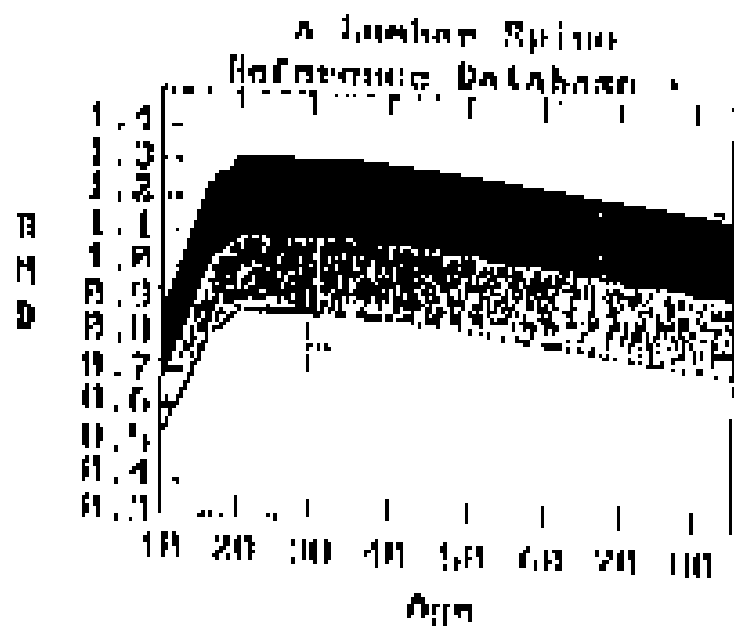
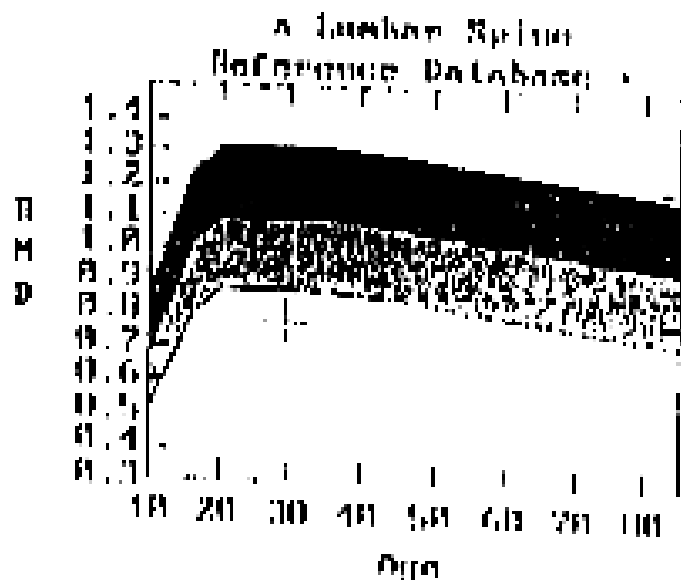
P88149680 Wed 14 Aug 1996 11:23

Name: ROM ZENI



ZAKŁAD DIAGNOSTYKI PRZEBIĄGOWEJ
UKŁADU KOSTNO-SŁABOWEGO
PRACOWNIA DENSYTOMETRII KOŚCI
CENTRUM OSTEOPOROZY "OSTEOMED"
02-380 Warszawa, ul. Białołęcka 4 (przy Dickensa)
Tel. 022 40 00 00

Densytogram kości - szyjka kości udowej



Densytogram kości - kręgosłup lędźwiowy